AAMS Internal Medicine & Therapeutics
ISSN: 2834-7102 (Print) | eISSN: 2834-7103 (Online)
Volume 07, Issue 10, Pages 16-30
DOI: 10.4103/aams.04987001
ORIGINAL ARTICLE

CHRONIC HEPATITIS C: MODERN APPROACHES TO DIAGNOSIS, CLINICAL MANAGEMENT, AND ANTIVIRAL TREATMENT

Ammar abdullah gharade[1], Mohd saud[2], Syed Abdullah Deebaz Nomani[3], Mohd Tazeem[4],

Group 337, Samarkand state medical university[1,2,3], Group 333, Samarkand state medical university[4],

Received: 2026-10-06 · Accepted: 2026-10-28

Abstract

Chronic hepatitis C is a persistent viral infection caused by the hepatitis C virus (HCV), which primarily affects the liver and may progressively lead to hepatic fibrosis, cirrhosis, and hepatocellular carcinoma. The disease represents an important global public health concern because its early stages are frequently asymptomatic, allowing liver injury to develop before clinical manifestations become apparent. Advances in molecular diagnostics and direct-acting antiviral agents have significantly improved the identification and treatment of infected individuals. Modern diagnostic strategies combine serological screening, molecular confirmation of viral replication, biochemical assessment, and non-invasive evaluation of liver fibrosis. Current antiviral medications provide high cure rates, generally exceeding 95% in appropriately treated populations. Nevertheless, delayed diagnosis, limited access to healthcare, reinfection, comorbid conditions, and advanced liver disease remain important clinical challenges. This article reviews the epidemiological characteristics, pathogenesis, clinical manifestations, diagnostic approaches, and contemporary treatment strategies for chronic hepatitis C. Particular attention is given to early detection, individualized antiviral therapy, prevention of disease progression, and long-term monitoring.

Keywords: chronic hepatitis C, hepatitis C virus, HCV RNA, liver fibrosis, cirrhosis, hepatocellular carcinoma, direct-acting antivirals, antiviral therapy, diagnosis, sustained virological response.

1. Introduction

Chronic hepatitis C is a significant infectious disease characterized by persistent replication of the hepatitis C virus and gradual inflammatory damage to hepatic tissue. The virus belongs to the Flaviviridae family and contains a single-stranded positive-sense RNA genome. Following infection, HCV primarily targets hepatocytes, where viral replication and interactions with the host immune system contribute to chronic inflammation and progressive structural changes in the liver. Unlike some other viral infections, hepatitis C frequently develops without obvious early symptoms. Consequently, many individuals remain unaware of their infection for years and are diagnosed only after abnormalities in liver function or signs of advanced hepatic disease appear.

The global burden of hepatitis C remains substantial. According to the World Health Organization, approximately 47 million people were living with chronic HCV infection in the latest global estimates

© 2026 AAMS Internal Medicine & Therapeutics. All rights reserved.

reported in 2026. The infection is associated with considerable morbidity and mortality, mainly through complications such as liver cirrhosis and hepatocellular carcinoma. Although effective antiviral medications are now widely available in many healthcare systems, a considerable proportion of infected individuals remain undiagnosed or have not received appropriate treatment. [1]

HCV is transmitted predominantly through exposure to infected blood. Important transmission pathways include unsafe medical injections, inadequately sterilized medical or cosmetic instruments, transfusion of unscreened blood products, and sharing needles or other injection equipment. Transmission through sexual contact and from an infected mother to her child is also possible, although the probability varies according to individual circumstances and associated risk factors. The infection is not ordinarily transmitted through hugging, sharing food, drinking from the same glass, or other routine social interactions.

The natural course of hepatitis C is variable. Some individuals spontaneously eliminate the virus during the acute phase, whereas others develop persistent infection. Chronic inflammation may continue for many years and gradually stimulate collagen deposition, extracellular matrix accumulation, and the development of hepatic fibrosis. Advanced fibrosis may progress to cirrhosis, portal hypertension, liver failure, and primary liver cancer. The rate of progression is influenced by several factors, including age at infection, alcohol consumption, metabolic disorders, obesity, diabetes mellitus, and coinfection with hepatitis B virus or human immunodeficiency virus.

The introduction of direct-acting antiviral medications has fundamentally changed the management of chronic hepatitis C. These agents directly inhibit essential viral proteins and interrupt different stages of viral replication. Unlike older interferon-based treatment approaches, modern regimens are predominantly oral, have shorter treatment durations, and are associated with substantially improved tolerability. The availability of highly effective antiviral therapy makes early diagnosis and timely treatment essential components of contemporary hepatitis C management.

The purpose of this article is to examine the principal clinical characteristics of chronic hepatitis C, describe modern diagnostic methods, evaluate current therapeutic approaches, and emphasize the importance of comprehensive patient follow-up and preventive strategies.

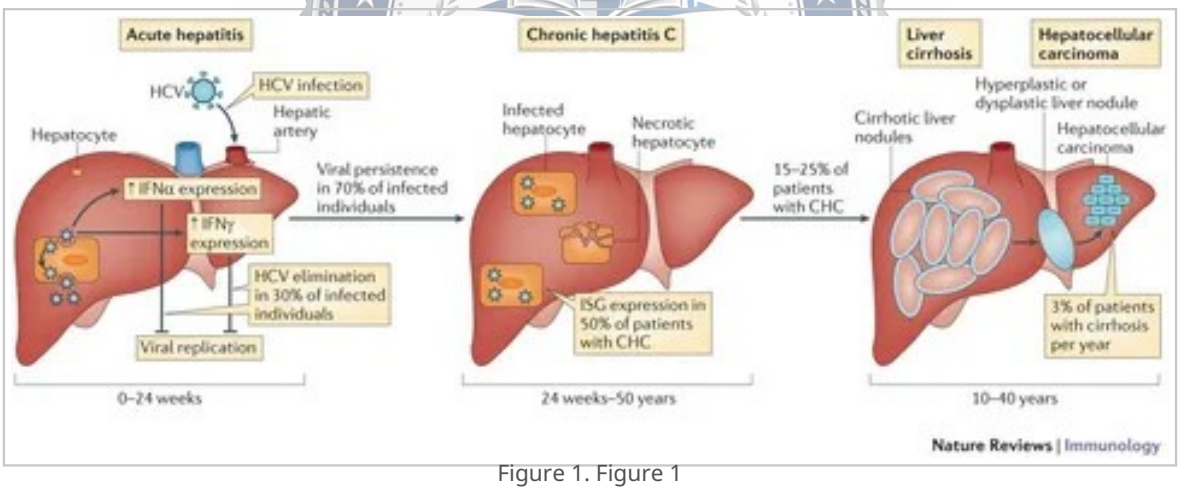

Figure 1. Figure 1

2. Materials and Methods

This article was prepared as a narrative review of scientific literature, clinical recommendations, and international guidance concerning chronic hepatitis C. The review focused on epidemiology, viral pathogenesis, clinical presentation, laboratory diagnosis, assessment of hepatic fibrosis, antiviral treatment, and prevention of disease-related complications. Relevant information was considered from international publications and recommendations issued by the World Health Organization, the American Association for the Study of Liver Diseases, and the Infectious Diseases Society of America.

The diagnostic section was organized around the principal stages of clinical assessment. These included identification of individuals with possible exposure to HCV, serological screening for anti-HCV antibodies, confirmation of active infection using molecular detection of HCV RNA, evaluation of liver biochemical parameters, and assessment of fibrosis severity. Particular attention was given to the clinical interpretation of alanine aminotransferase, aspartate aminotransferase, bilirubin, albumin,

© 2026 AAMS Internal Medicine & Therapeutics. All rights reserved.

platelet count, and non-invasive fibrosis assessment methods.
The therapeutic review examined contemporary direct-acting antiviral regimens, including combinations of viral protease inhibitors, NS5A inhibitors, and NS5B polymerase inhibitors. The analysis also considered treatment eligibility, potential drug interactions, the importance of adherence, and the assessment of sustained virological response after therapy.
As this work represents a narrative literature review rather than an original clinical investigation, no patient recruitment, experimental intervention, or independent statistical analysis was performed. Therefore, the findings presented below summarize established clinical knowledge and published evidence rather than reporting newly collected patient data.

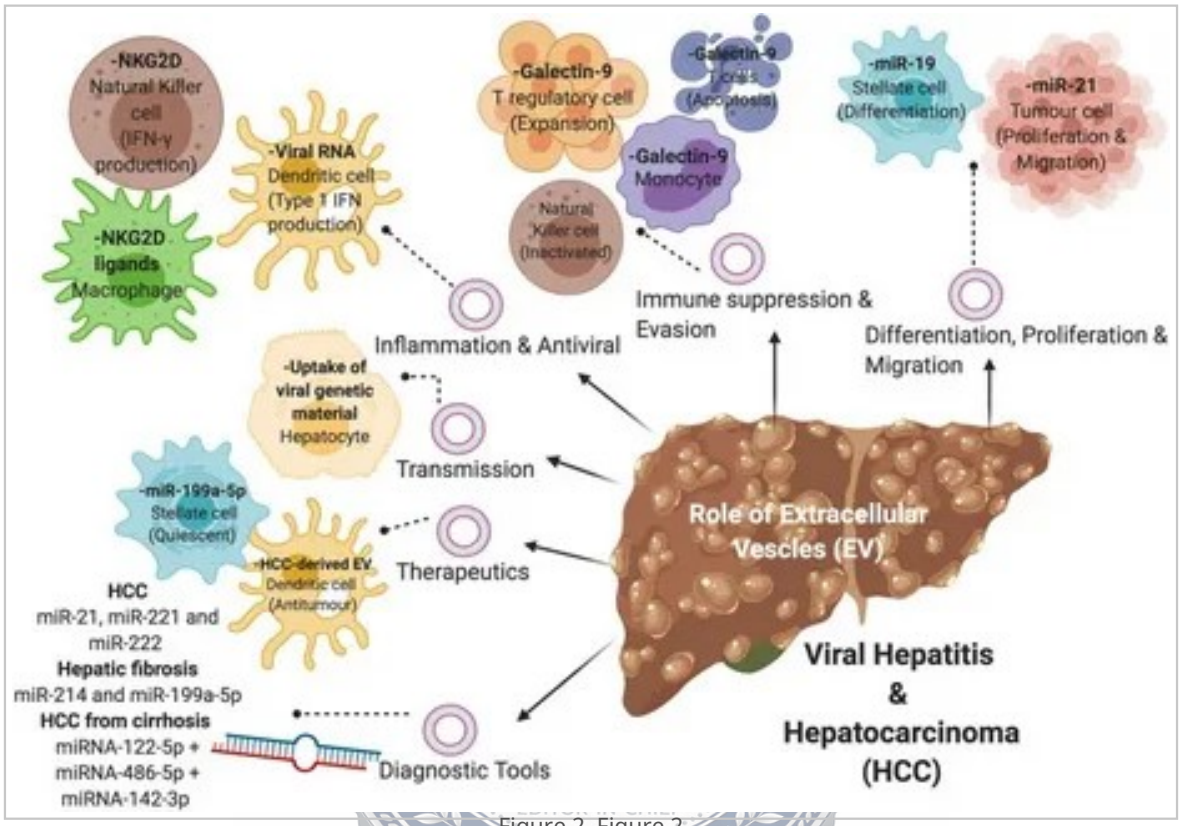

Figure 2. Figure 2

3. Results

Epidemiological Characteristics and Risk Factors
Chronic hepatitis C occurs worldwide and affects populations with different demographic and socioeconomic characteristics. The distribution of infection is associated with historical patterns of blood transfusion, healthcare-associated exposure, injection-related practices, and access to safe medical procedures. Individuals may acquire the infection through a single significant exposure or repeated contact with contaminated blood.
The principal risk factors include previous blood transfusions performed without adequate screening, use of non-sterile medical instruments, sharing needles and syringes, unsafe tattooing or piercing procedures, and occupational exposure to infected blood. People receiving hemodialysis, individuals living with HIV, and persons with a history of injection drug use may require particular attention during screening and follow-up.
A major epidemiological difficulty is the asymptomatic nature of early infection. Individuals may have normal or only slightly elevated liver enzyme levels despite active viral replication. Consequently, relying exclusively on clinical symptoms or routine biochemical testing is insufficient for identifying all infected patients. Screening strategies based on risk assessment and appropriate population-level recommendations are therefore essential.
Pathogenesis and Progression of Liver Injury
After entering the bloodstream, HCV reaches the liver and infects hepatocytes. Viral replication occurs within the cytoplasm of these cells. The host immune response attempts to eliminate infected cells

© 2026 AAMS Internal Medicine & Therapeutics. All rights reserved.

and suppress viral replication; however, the virus can persist by altering its genetic structure and interfering with immune recognition.

Persistent viral activity contributes to chronic inflammatory processes within hepatic tissue. Activated inflammatory cells release cytokines and other signaling molecules that stimulate hepatic stellate cells. These cells gradually acquire a fibrogenic phenotype and produce excessive extracellular matrix components, particularly collagen. As the process continues, normal hepatic architecture becomes progressively disrupted.

The severity of liver damage varies considerably between individuals. Some patients experience relatively slow fibrosis progression, while others develop advanced fibrosis or cirrhosis over a shorter period. Alcohol consumption, metabolic dysfunction-associated steatotic liver disease, obesity, diabetes, and other chronic liver conditions may accelerate disease progression. Once cirrhosis develops, patients are at increased risk of portal hypertension, ascites, variceal bleeding, hepatic encephalopathy, and hepatocellular carcinoma.

Clinical Manifestations

The clinical presentation of chronic hepatitis C ranges from an entirely asymptomatic condition to advanced chronic liver disease. During the early stages, patients may report nonspecific complaints such as persistent fatigue, reduced physical endurance, weakness, appetite disturbances, nausea, and occasional discomfort in the right upper abdominal region. These manifestations are not specific to HCV and cannot establish the diagnosis independently.

Some patients experience extrahepatic manifestations, which may occur because of immune-mediated mechanisms associated with chronic infection. These include mixed cryoglobulinemia, certain forms of glomerulonephritis, dermatological conditions, and metabolic disturbances. Chronic HCV infection may also be associated with insulin resistance and an increased risk of developing type 2 diabetes mellitus.

As hepatic fibrosis advances, clinical findings may become more evident. Patients with cirrhosis can develop hepatomegaly or splenomegaly, thrombocytopenia, peripheral edema, ascites, jaundice, and signs of portal hypertension. In decompensated disease, hepatic encephalopathy and gastrointestinal bleeding may occur and require urgent medical intervention.

An important clinical feature is the possible absence of a direct relationship between symptom severity and the degree of liver damage. A patient with few complaints may already have significant fibrosis. For this reason, objective laboratory and imaging-based assessment is necessary even when clinical manifestations are mild.

Laboratory and Instrumental Diagnosis

The diagnosis of chronic hepatitis C requires confirmation of active viral infection. The initial screening test is generally the detection of antibodies against HCV. A positive anti-HCV result indicates previous exposure to the virus but does not necessarily demonstrate ongoing infection. Antibodies may remain detectable after spontaneous viral clearance or successful antiviral treatment.

Active infection is confirmed through the detection of HCV RNA using a nucleic acid amplification test, commonly performed by polymerase chain reaction. A positive HCV RNA result indicates current viral replication and provides the basis for further clinical assessment and treatment planning. Where available, reflex testing, in which HCV RNA analysis is automatically performed after a positive antibody result, can reduce delays and improve linkage to care. [1,2]

Biochemical evaluation is important for determining the functional condition of the liver and identifying possible complications. Alanine aminotransferase and aspartate aminotransferase are commonly used indicators of hepatocellular injury. Their elevation may suggest active liver inflammation, although normal values do not exclude chronic HCV infection or significant fibrosis. Bilirubin, albumin, and prothrombin time or international normalized ratio provide additional information about hepatic function, particularly in advanced disease.

A complete blood count is useful for identifying thrombocytopenia, which may indicate portal hypertension or advanced fibrosis in an appropriate clinical context. Renal function assessment is also important because kidney impairment can influence treatment selection and monitoring. Testing for hepatitis B and HIV coinfection is recommended as part of the pretreatment evaluation.

Assessment of liver fibrosis is a central component of disease staging. Transient elastography provides a non-invasive estimate of liver stiffness and may help identify advanced fibrosis or cirrhosis. Blood-based indices, including the Fibrosis-4 index and the AST-to-platelet ratio index, can also support fibrosis assessment. In selected cases, additional imaging or liver biopsy may be considered

© 2026 AAMS Internal Medicine & Therapeutics. All rights reserved.

when diagnostic uncertainty remains or when another liver disease is suspected.
Ultrasonography is particularly useful in patients with suspected cirrhosis and during surveillance for hepatocellular carcinoma. However, conventional ultrasound cannot independently confirm active HCV infection and should not replace molecular testing.

Modern Antiviral Treatment

The development of direct-acting antiviral agents represents the most important therapeutic advance in the management of chronic hepatitis C. These medications target specific proteins required for viral replication. NS3/4A protease inhibitors interfere with viral protein processing, NS5A inhibitors disrupt viral replication and assembly, and NS5B polymerase inhibitors prevent the synthesis of viral RNA.
Modern treatment is based primarily on pangenotypic combinations that are active against multiple HCV genotypes. Commonly recommended options for eligible treatment-naive adults include sofosbuvir/velpatasvir and glecaprevir/pibrentasvir. Depending on the regimen and clinical characteristics, treatment may last approximately 8–12 weeks in many uncomplicated cases. The choice of medication and treatment duration must be determined by a qualified clinician after assessment of cirrhosis status, previous antiviral exposure, renal and hepatic function, pregnancy considerations, and potential drug interactions. [2,3]
Before treatment, clinicians should evaluate HCV RNA, complete blood count, hepatic biochemical parameters, renal function, and relevant coinfections. Hepatitis B screening is particularly important because HBV reactivation may occur during or after HCV treatment in patients with current or previous HBV infection. Medication reconciliation is also essential because some antiviral agents interact with commonly prescribed drugs.
Treatment effectiveness is generally evaluated by measuring HCV RNA at least 12 weeks after completion of therapy. An undetectable viral RNA level at this point is defined as a sustained virological response at 12 weeks, or SVR12. This outcome is accepted as evidence of virological cure in the vast majority of treated patients. Current international recommendations report cure rates above 95% with appropriate direct-acting antiviral therapy. [1,2]
Although treatment is highly effective, successful outcomes depend on appropriate regimen selection and adherence. Patients should receive clear information about the importance of completing the prescribed course and consulting a clinician before starting new medications or supplements. Individuals with previous treatment failure may require specialist assessment and a specific retreatment strategy.

Prevention and Long-Term Monitoring

Prevention of HCV infection requires a combination of safe healthcare practices, blood safety measures, risk-reduction interventions, and public awareness. Medical facilities should use properly sterilized instruments, follow infection-control standards, and ensure that donated blood is appropriately screened. People who inject drugs should have access to sterile injection equipment and harm-reduction services.
There is currently no effective vaccine against hepatitis C. Therefore, prevention depends primarily on avoiding exposure to infected blood and identifying infection early. Vaccination against hepatitis A and hepatitis B should be considered for susceptible patients with chronic liver disease because additional viral hepatitis may increase the risk of hepatic complications.
Patients who achieve SVR12 generally have a substantially reduced risk of liver-related complications. However, viral eradication does not completely reverse established cirrhosis or eliminate every risk associated with advanced hepatic damage. Individuals with cirrhosis should continue regular hepatocellular carcinoma surveillance, generally using liver ultrasound every six months according to relevant clinical recommendations. Patients with ongoing exposure risks may also require periodic HCV RNA testing to identify reinfection. [4,5]

The American Archives OF MEDICAL SCIENCES

© 2026 AAMS Internal Medicine & Therapeutics. All rights reserved.

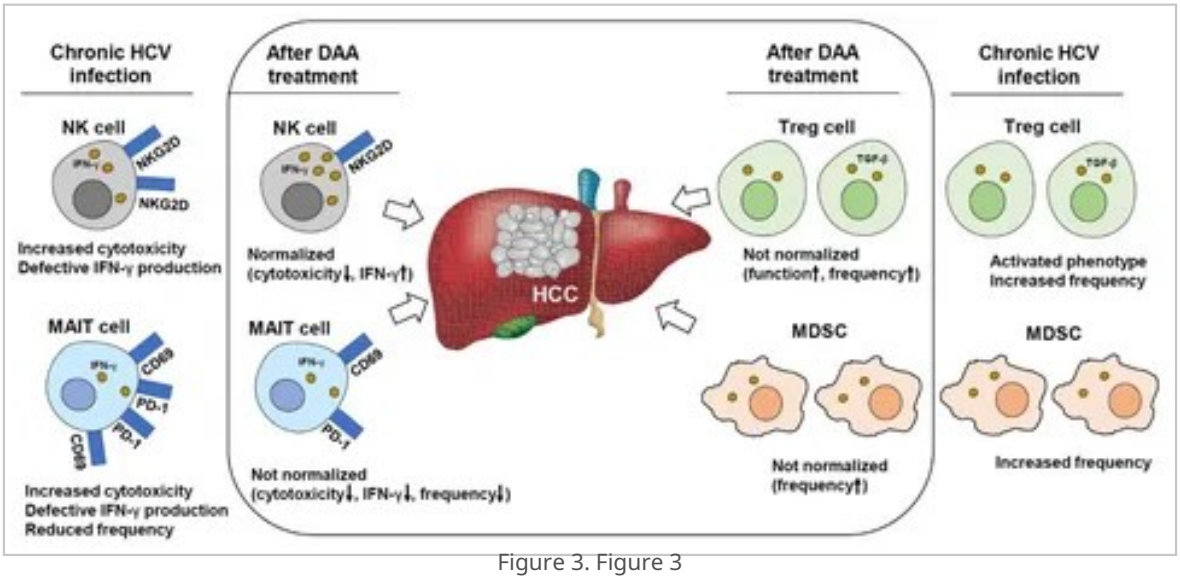

Figure 3. Figure 3

4. Discussion

Chronic hepatitis C remains an important clinical and public health challenge despite the availability of highly effective antiviral treatment. One of the main difficulties in controlling the disease is the considerable number of individuals who remain undiagnosed. Because early infection is frequently asymptomatic, patients may seek medical attention only after developing persistent fatigue, abnormal biochemical findings, or complications associated with advanced liver damage. This situation emphasizes the importance of systematic screening and accessible diagnostic services.

The diagnostic process should be based on a clear distinction between previous exposure and active infection. Anti-HCV antibody testing is valuable for screening, but a positive result alone cannot establish current viral replication. Confirmation through HCV RNA testing is therefore essential. Integrating these two stages into a single diagnostic pathway can reduce the number of patients lost between screening and confirmation.

Another important issue is the accurate evaluation of hepatic fibrosis. Liver enzyme concentrations do not always reflect the actual extent of structural liver damage. Some patients with normal aminotransferase levels may have clinically significant fibrosis. Non-invasive methods such as transient elastography and validated blood-based indices provide useful information and reduce the need for invasive liver biopsy in many clinical situations. Nevertheless, these methods should be interpreted together with clinical history, laboratory findings, and imaging results.

The introduction of direct-acting antivirals has changed the prognosis of chronic hepatitis C. Earlier interferon-based regimens were associated with prolonged treatment, substantial adverse effects, and variable response rates. Modern oral antiviral combinations are generally better tolerated and achieve sustained virological response in the overwhelming majority of appropriately treated patients. As a result, the principal challenge has increasingly shifted from the biological effectiveness of treatment toward identifying infected individuals, ensuring access to medication, and maintaining continuity of care.

The clinical management of patients with advanced liver disease requires additional attention. Although viral eradication reduces ongoing hepatic inflammation and the risk of future complications, patients with established cirrhosis remain vulnerable to hepatocellular carcinoma and portal hypertension. Therefore, achieving virological cure should not be considered the endpoint of medical follow-up in this group. Long-term surveillance and management of cirrhosis-related complications remain necessary.

Extrahepatic manifestations also demonstrate that chronic HCV infection is not exclusively a liver disease. Immune-complex-related disorders, renal involvement, metabolic abnormalities, and selected dermatological conditions may influence patient quality of life and clinical outcomes. Comprehensive assessment should therefore include relevant systemic manifestations, especially in patients with unexplained renal abnormalities, vasculitic symptoms, or metabolic disturbances.

The relationship between hepatitis C and metabolic disorders deserves particular consideration.

The American Archives OF MEDICAL SCIENCES

Obesity, insulin resistance, and type 2 diabetes may coexist with chronic HCV infection and contribute to an unfavorable hepatic profile. Lifestyle modification, including avoidance of excessive alcohol consumption, maintenance of a healthy body weight, balanced nutrition, and regular physical activity, should complement antiviral treatment.

Several limitations should be recognized when interpreting this review. It is a narrative synthesis rather than a systematic review or meta-analysis, and it does not present original patient data. Differences in national screening policies, medication availability, healthcare resources, and clinical guidelines may also influence the practical application of diagnostic and therapeutic recommendations. Future research should focus on improving access to simplified testing pathways, evaluating long-term outcomes after viral eradication, and developing more effective strategies to prevent reinfection.

Overall, the available evidence supports an integrated approach that combines early detection, accurate confirmation of active infection, assessment of liver fibrosis, individualized antiviral treatment, and appropriate long-term follow-up. Expanding access to these services is essential for reducing the global burden of hepatitis C.

5. Conclusion

Chronic hepatitis C is a potentially progressive viral disease that may remain clinically silent for many years while causing continuous hepatic injury. Without timely diagnosis and treatment, persistent infection can result in advanced fibrosis, cirrhosis, portal hypertension, and hepatocellular carcinoma. Modern diagnostic methods, particularly the combination of anti-HCV antibody screening and confirmatory HCV RNA testing, provide a reliable foundation for identifying active infection. Non-invasive fibrosis assessment further improves clinical evaluation and supports appropriate treatment planning.

Direct-acting antiviral medications have transformed the management of chronic hepatitis C by providing short-course, highly effective treatment with favorable tolerability. Achieving sustained virological response substantially improves the long-term prognosis of most patients. Nevertheless, individuals with established cirrhosis require continued monitoring, and preventive measures remain essential because reinfection is possible and no effective vaccine is currently available.

In conclusion, early diagnosis, timely antiviral treatment, patient education, and continuous clinical monitoring are the principal components of effective chronic hepatitis C management. Strengthening screening programs and improving access to modern antiviral therapy can contribute significantly to reducing HCV-related complications and achieving broader public health goals.

The American Archives OF MEDICAL SCIENCES EDITOR-IN-CHIEF

AUTHOR INFORMATION

Ammar abdullah gharade[1], Mohd saud[2], Syed Abdullah Deebaz Nomani[3], Mohd Tazeem[4],

Group 337, Samarkand state medical university[1,2,3], Group 333, Samarkand state medical university[4],

REFERENCES

1. World Health Organization. Hepatitis C. WHO Fact Sheet. 28 July 2026. Available at: https://www.who.int/news-room/fact-sheets/detail /hepatitis-c
2. Bhattacharya D, Aronsohn A, Price J, Lo Re V. AASLD-IDSA 2023 Clinical Practice Guidance Update for Testing, Managing, and Treating Hepatitis C Virus Infection. Clinical Infectious Diseases. 2023;77(5):632–665.

© 2026 AAMS Internal Medicine & Therapeutics. All rights reserved.

REFERENCES · CONTINUED

3. European Association for the Study of the Liver. EASL recommendations on treatment of hepatitis C: Final update of the series. Journal of Hepatology. 2020;73(5):1170–1218.

4. Ghany MG, Morgan TR. Hepatitis C Guidance 2019 Update: American Association for the Study of Liver Diseases–Infectious Diseases Society of America Recommendations for Testing, Managing, and Treating Hepatitis C Virus Infection. Hepatology. 2020;71(2):686–721.

5. American Association for the Study of Liver Diseases and Infectious Diseases Society of America. HCV Guidance: Recommendations for Testing, Managing, and Treating Hepatitis C. Available at: https://www.hcvguidelines.org/

6. Polaris Observatory HCV Collaborators. Global change in hepatitis C virus prevalence and cascade of care between 2015 and 2020: a modelling study. The Lancet Gastroenterology & Hepatology. 2022;7(5):396–415.

7. Muir AJ. The rapid evolution of treatment strategies for hepatitis C. American Journal of Gastroenterology. 2014;109(5):628–635.

8. Pawlotsky JM, Negro F, Aghemo A, et al. EASL recommendations on treatment of hepatitis C: Final update of the series. Journal of Hepatology. 2020;73(5):1170–1218.

9. Carrat F, Fontaine H, Dorival C, et al. Clinical outcomes in patients with chronic hepatitis C after direct-acting antiviral treatment: a prospective cohort study. The Lancet. 2019;393(10179):1453–1464.

10. Spearman CW, Dusheiko GM, Hellard M, Sonderup M. Hepatitis C. The Lancet. 2019;394(10207):1451–1466.

The American Archives OF MEDICAL SCIENCES EDITOR-IN-CHIEF

© 2026 AAMS Internal Medicine & Therapeutics. All rights reserved.

Indexed & Abstracted In

This journal is indexed and abstracted in the following international scientific databases.

Google Scholar

ISSN

ORCID

CiteFactor

ResearchBib

DOI

Zenodo

Crossref

Grammarly



Article Verification

Scan the QR code to verify the authenticity of this article

DOI: 10.4103/aams.04987001

Google Scholar full text: https://www.aams-journal.us/scholar/0e01965b-2e5d-489a-a917-c7f18776c6bd.html

© 2026 AAMS Internal Medicine & Therapeutics. All rights reserved.